



*Case Report*

**Combined Ultrasound and IVU for the Management of Childhood Urolithiasis: A Case Report**

**Fathinul Fikri A. S. and Abdul Jalil Nordin**

*Centre for Diagnostic Nuclear Imaging, Universiti Putra Malaysia, 43400 Serdang, Selangor, Malaysia*

**ABSTRACT**

The incidence of ureteric calculus as a cause for severe abdominal pain in children is mounting, especially in the tropical country. The course of illness may be non-specific but a swift detection via non-invasive imaging modalities singly or in combination may avert unnecessary radiation hazard and futile surgery in a young child. In this paper, we discussed a case of an 11 year-old boy who was presented with a sudden onset of the right side severe abdominal colic whose a bedside ultrasound was positive for hydronephrosis for which localisation of stone was further confirmed via a low dose limited intravenous urography (IVU). It is important to note that data available on the value of a combined ultrasound and the limited IVU in an emergency setting when urolithiasis is being suspected in children with abdominal pain are particularly scarce. Hence, this case documented the potential value of a combined ultrasound and a limited IVU study as a unique combined armamentarium used in a suspected childhood urolithiasis in the tropics.

**Keywords: Child, abdominal colic, ureteric calculus, limited IVU**

**INTRODUCTION**

Prevalence of urolithiasis in children is largely attributable to the change in socio-economic conditions and climatological phenomena. Its incidence in the tropical

countries is on the rise (Robertson, 2003). Traditionally in children, upper tract stones are associated with urinary tract anomalies and infection rather than metabolic disturbances. Suspicion of stones in a child with acute severe abdominal pain is crucial when there is no other associated symptom confounding the renal colic, especially in children living in the tropics. Robertson further stressed the problem of increasing renal stone in the tropics, where the risk of stone formation is confounded by low urine volume (Robertson,

*Article history:*

Received: 20 June 2011

Accepted: 22 September 2011

*Email addresses:*

ainurff@gmail.com (Fathinul Fikri A. S.),

drimaging@yahoo.com (Abdul Jalil Nordin)

\*Corresponding Author

2003). Immediate suspicion of the renal stone manifestation may avert excessive and time consuming investigation for other non-specific causes of pain in children.

There are varieties of diagnostic tools employed in evaluating childhood abdominal pain, and these include KUB, IVU, ultrasound (US) or computed tomography (CT). In our experience, the use of a combined bedside ultrasound and a limited series IVU is essential in excluding ureterolithiasis in children with acute or severe abdominal pain. CT examination, though it may produce more accurate results as compared to IVU and ultrasound, it imposes escalating radiation dose to the radio-sensitive tissue in the child bearing age. Meanwhile, IVU has a sensitivity of 64% to 97% as compared to ultrasound (74%) when hydronephrosis is added as a positive sign for a ureteric stone (Miler *et al.*, 1998). The accuracy of US/KUB was found to be 71% lower than the accuracy of IVU alone. As for a combination of US/KUB, it has a sensitivity of 79% compared to CT (93%) (Ripolles *et al.*, 2004). Although computerized tomography is more sensitive in detecting urolithiasis than ultrasound, the difference in the usefulness between the 2 radiological tests may not be clinically significant (Carlo *et al.*, 2009). Nonetheless, data on the value of a combined USG and a limited IVU are scarce. This report highlights its potential value when the ultrasound is positive for hydronephrosis whilst optimising the radiation dose to the young patient.

## CASE STUDY

This case study involved an 11 year-old boy who presented with severe intermittent right abdominal pain 2 hours prior to hospital admission. He was fretful without pallor or jaundice. The abdomen was generally soft without guarding or rebound tenderness. Intramuscular morphine (2.0mg) was given but was inadequate as the child continued to be restless despite the sedative effects. Intravenous access and urinary catheterisation were performed. An emergency bedside abdominal ultrasound was ordered and this revealed mild separation of the right renal pelvis without recognisable stones within (*see* Fig.1). A control anterior-posterior (AP) abdominal radiograph and an immediate 15-minute IVU filming were also performed after the intravenous administration of low osmolar contrast medium. The pyelographic IVU phase revealed a small filling defect in the right upper ureter causing mild right hydronephrosis

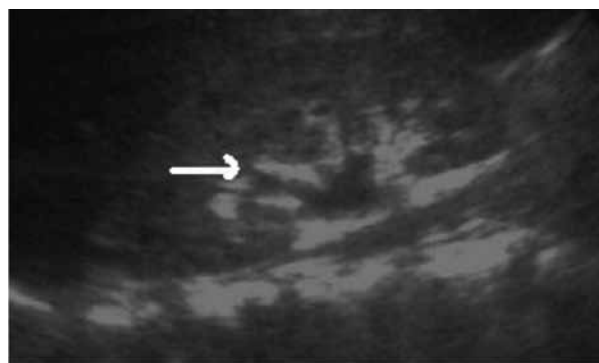


Fig.1: Transaxial ultrasound image shows a mild separation of the right central renal echo-complex (arrowed)

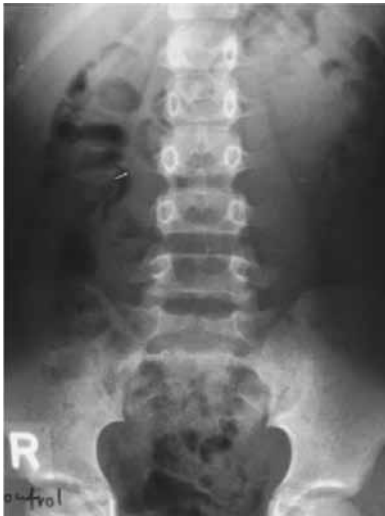

Fig.2: There is a small faint opacity seen in the course of the right upper ureter representing a stone (arrowed)

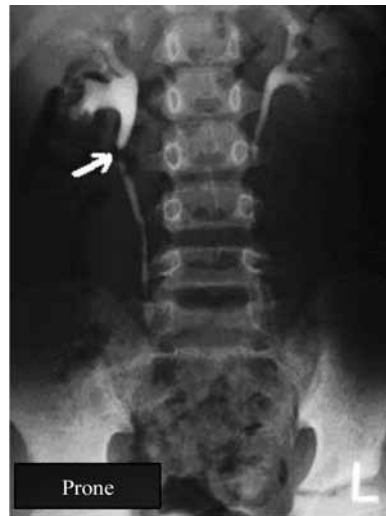

Fig.3: IVU – 15-minute AP film; there is mild right sided hydronephrosis and proximal right hydroureter with a filling defect seen in the right upper ureter (arrowed)

favouring partial right upper ureteric stone obstruction, as shown in Fig.2 and Fig.3. The stone was removed following a flexible ureteroscopic procedure. This report highlights the value of a combined US and a limited series of IVU in children with acute abdominal pain for which the incidence of urolithiasis is escalating among those who reside in the tropics.

## DISCUSSION

Abdominal pain is a common problem in children. Although most children with acute abdominal pain have self-limited conditions, the pain may herald a surgical or medical emergency. The most difficult challenge is making a timely diagnosis so that treatment can be initiated and morbidity prevented. Most children with urolithiasis present symptomatically, usually with flank or abdominal pain. Approximately 15 to 20 percent are asymptomatic, primarily young children who are diagnosed with stone detection when abdominal imaging is performed for other purposes (Coward *et al.*, 2005). Traditionally, upper urinary tract stones in children are associated more frequently with metabolic disturbances rather than with urinary tract anomalies and infection (Coward *et al.*, 2005).

The current study documents the value of a combined ultrasound abdomen and a limited IVU series in diagnosing a ureteric stone in a young boy presented with severe acute right abdominal pain. In the tropics, the prevalence of the ureteric stone in children has gained a considerable attention from the treating physicians for which the attributing factor is largely due to the patient's concentrated urine volume. The use of ultrasound in investigating abdominal pain in children is feasible as it provides a quick revelation of solid organ abnormality in question. In a prospective study, fifty-eight patients with renal colic, while fifty-eight of the

104 patients enrolled in the study were diagnosed with renal colic, and the overall sensitivity and specificity of bedside ultrasonography for the detection of hydronephrosis were found to be 86.8% and 82.4%, respectively (Romolo *et al.*, 2005). In the report of the current work, the use of a limited series IVU technique after a positive ultrasound abdomen for hydronephrosis has led to as a swift localisation of a ureteric stone. There are hardly any data on the value of the combined US and the limited IVU technique when compared to other armamentariums in the evaluation of childhood abdominal pain when urolithiasis is being suspected as a cause. The low dose limited IVU technique has not been given a focus in evaluating childhood urolithiasis as most of the concerns related to the reduced radiation dose are limited to renal trauma (Smith *et al.*, 2003). A concern on the absorbed skin dose has been much debated when CT is used as a standard tool on younger children Liu Wesler *et al.*, 2000). Of late, a new digital technique known as digital tomosynthesis was found to have a diagnostic quality in 95.5% with the mean of 56% of dose reduction when used for IVU (Wells IT *et al.*, 2011).

## CONCLUSION

Urolithiasis in the pediatric population has evolved from a mere clinical curiosity to a disease process worthy of thoughtful and rigorous scientific study when investigating children with severe abdominal pain especially in tropical countries. This report has documented the potential value of a combined ultrasound and a limited series of IVU as a first line investigation method in an emergency setting involving a child with severe abdominal pain in the tropics.

## REFERENCES

- Robertson, W. G. (2003). Renal stones in the tropics. *Semin. nephrol.*, 23, 77-87.
- Miler, O. F., Rineer, S. K., & Reichard, S. R. (1998). Prospective comparison of unenhanced spiral computed tomography and intravenous urogram in the evaluation of acute flank pain. *Urology*, 52, 982-987.
- Ripolles, T., Agramunt, M., Errando, J., Martinez, M. J., & Coronel B. (2004). Suspected ureteric colic, plain film and sonography versus unenhanced helical CT: A prospective study of 66 patients. *Eur. Radiol.*, 14(1), 129-136.
- Carlo, P., Jeanne, S. C., Andres, S., Cynthia, L. S., & Ilina, R. (2009). Ultrasound Versus Computerized Tomography for Evaluating Urolithiasis. *The Journal of Urology*, 182(4), 1.
- Coward, R. J., Peters, C. J., Duffy, P. G., Corry, D., & Kellet, M. J. (2003). Epidemiology of paediatric renal stone disease in the UK. *Arch Dis. Child*, 88, 962-5.
- Romolo, J. G. & Kurt, H. (2005). Emergency ultrasound and urinalysis in the evaluation of flank pain. *Academic Emergency Medicine*, 12(12), 1180-1184.
- Liu Wesler, S. J., Kenny, B. J., Rainbow, A. J., & Stevenson, G. W. (2000). Low dose non-enhanced helical CT of renal colic: Assessment of ureteric stone detection and measurement of effective dose equivalent. *Radiology*, 215, 51-54.
- Wells, I. T., Raju, V. M., & Rowberry, B. K. (2011). Digital tomosynthesis- a new lease of life for the intravenous urogram? *Br. J. Radiol.*, 84(1001), 464-8.
- Smith, J. K., & Kenney, P. J. (2003). Imaging of renal trauma. *Radiol. Clin. North Am.*, 41(5), 1019-1035.